

Accepted Manuscript**Accepted Manuscript (Uncorrected Proof)**

Title: Effects of Exposure to Aflatoxin G1 on the Plasma Biochemical Factors and Histopathological Properties of Renal Tissue in Mice

Authors: Touraj Zamir-Nasta¹, Arash Ahmadi², Moein Yazdkhasti³, Mona Pazhouhi¹, Cyrus Jalili^{4,*}, Kosar Rezaei¹

1.MSc., Department of Anatomy, School of Medicine, Kermanshah University of Medical Sciences, Kermanshah, Iran.

2.PhD, Department of Pathobiology, Faculty of Veterinary Medicine, Shahid Chamran University, Ahvaz, Iran.

3.PhD, Department of clinical sciences, Faculty of Veterinary Medicine, Lorestan University, Khorramabad, Iran.

4.PhD, Medical Biology Research Center, Health Technology Institute, Kermanshah University of Medical Sciences, Kermanshah, Iran.

*Corresponding Author: Dr. Cyrus Jalili Email: cjalili@yahoo.com

Medical Biology Research Center, Health Technology Institute, Kermanshah University of Medical Sciences, Kermanshah, Iran.

To appear in: **Iranian Journal of Toxicology**

Received date: 2021/01/7

Revised date: 2021/03/1

Accepted date: 2021/03/6

This is a “Just Accepted” manuscript, which has been examined by the peer-review process and has been accepted for publication. A “Just Accepted” manuscript is published online shortly after its acceptance, which is prior to technical editing and formatting and author proofing. *Iranian Journal of Toxicology* provides “Just Accepted” as an optional and free service which allows authors to make their results available to the research community as soon as possible after acceptance. After a manuscript has been technically edited and formatted, it will be removed from the “Just Accepted” Web site and published as a published article. Please note that technical editing may introduce minor changes to the manuscript text and/or graphics which may affect the content, and all legal disclaimers that apply to the journal pertain.

Please cite this article as:

Zamir-Nasta T, Ahmadi A, Yazdkhasti M, Pazhouhi M, Jalili C, Rezaei K. (In Press). Effects of Exposure to Aflatoxin G1 on the Plasma Biochemical Factors and Histopathological Properties of Renal Tissue in Mice. *Iranian Journal of Toxicology*. Just Accepted publication Mar. 6, 2021. Doi: <http://dx.doi.org/10.32598/IJT.15.2.787.1>
DOI: <http://dx.doi.org/10.32598/IJT.15.2.787.1>

ABSTRACT

Background: Among aflatoxins, the subtype aflatoxin G1 is one of the most toxic, commonly found in cereals, legumes, dairy and non-alcoholic beers. Aflatoxins have been known as nephrotoxic compounds. In this study, changes in the expression of aquaporin-1, the histopathology of renal tissue and plasma biochemical factors after exposure to aflatoxin G1 were investigated in mice.

Methods: Twenty-four adult male mice (weighing 20 ± 2 g) were divided into four groups of six. The control group received the vehicle (0.2 ml) and the three experimental groups were injected intraperitoneally with aflatoxin G1 at $20\mu\text{g}/\text{kg}$ for 7, 15 or 35 days, respectively. On days 7, 15 and 35, blood samples were drawn from the mice for biochemical analysis of plasma and the kidney tissues were sampled for real-time PCR and histopathological studies.

Results: The real PCR results showed a reduction in aquaporin-1 expression in the experimental groups compared to those in the controls ($P<0.05$). Also, the plasma concentrations of urea and creatinine were significantly increased in the experimental groups compared to those in the controls ($P<0.05$). Also, the serum sodium and potassium levels had decreased significantly compared to the controls ($P<0.05$). Various damages were observed in the ureters and glomeruli among the experimental groups compared to those in the controls.

Conclusions: Aflatoxin G1 had adverse effects on the renal tissue by reducing the expression of aquaporin-1. Subsequently, there were biochemical manifestations in the serum, consisting of changes in the concentrations of urea, creatinine, sodium and potassium, confirming the histopathological toxicity of aflatoxin G1.

Keywords: Aflatoxin G1, Toxicity, Urea, Creatinine, Renal damage, Mice

INTRODUCTION

Aflatoxins are toxic substances produced by the fungal species, *Aspergillus flavus* and *parasiticus* that grow rapidly in nutritious grains and vegetables, and secrete its toxins (1, 2). To date, 18 types of toxic compounds have been isolated from this fungus, collectively called aflatoxins, of which the four types aflatoxins B1, B2, G1 and G2 are the most toxic ones (3-5). Aflatoxins are known to be carcinogenic, mutagenic, teratogenic and immunosuppressive substances. These toxins inhibit several metabolic systems and lead to damages in the liver, kidneys, and heart. They are also known to cause high mortality in humans and animals, such as cattle. (6-9). Since the kidneys are the primary excretory pathway for some toxins, the high sensitivity of this organ to the toxins is crucial, thus they are well known for their nephrotoxicity (10-12). According to studies, aflatoxins' metabolites exert toxicity to the kidney nephrons even before being excreted in the urine (13, 14).

Numerous studies in various animal models have shown that aflatoxin B1 causes damage to kidney cells by developing abnormal changes in the biochemical markers of oxidative stress (12, 15, 16). Studies have also shown increases in blood urea, serum creatinine, uric acid and other renal marker enzymes after treatment with aflatoxin B1 or exposure to a combination of aflatoxins (12, 17). The kidneys in mice have been shown to be the most sensitive organ if exposed to aflatoxin B1 (18, 19). Pathological studies in other animal models have demonstrated histological damages, including renal tubular necrosis, cast formation, interstitial hemorrhage, glomerular damage, and tubular epithelial degeneration due to the toxic effect of aflatoxin B1 (13, 20).

Aquaporins are a group of transmembrane proteins whose role is to transport water based on concentration gradients using bilateral water channels in many tissues of the body (21). Aquaporin-1 is the first aquaporin to be discovered during an experiment to identify Rh blood group antigens in human erythrocytes (22). At least 9 aquaporins are expressed in renal tissue, with aquaporin-1 found in the proximal complex tubes and descending thin tubes but not in other urinary tracts (23). Among aflatoxins, the aflatoxin G1 is the most toxic one and is commonly found in animal and human foods, especially at high concentrations in cereals, such as corn, peanuts and non-alcoholic beer (24, 25). A previous study has suggested the role of aflatoxin G1 in disrupting spermatogenesis and reducing the sperm production and quality in mice (3).

Due to the high prevalence of kidney disease and the lack of definitive diagnosis on the etiology, aflatoxins are suspected as the cause of most kidney diseases in Iran (26). Most of the toxic effects of aflatoxin G1 on the kidneys have been studied either alone or in combination with other aflatoxin species. Given the importance of aflatoxin G1 in the community health and shortage of research on aflatoxin G1 toxicity in the kidneys, we aimed to investigate its effects on the renal tissue in mice. This study investigated the histopathological effects of aflatoxin B1 on the renal tissue and the biochemical changes, such as serum urea, creatinine, sodium and potassium in mice.

MATERIALS & METHODS

Laboratory Animals and Chemicals: Twenty-four adult male mice (weighing 20 ± 2 g) were used in this study. Standard experimental conditions included 12 hours of light and dark, the ambient temperature at $25\pm 2^{\circ}\text{C}$ and the relative humidity at $\%50\pm 10$. The aflatoxin G1 supply was purchased from Sigma (Cat. #: 1162-65-8; St. Louis, MO, USA) and dissolved in corn oil and ethanol (95:5v/v). Biochemical analysis kits were purchased from Pars Azmoun Company (Tehran, Iran). The mice were randomly divided into four groups of six each, consisting of one control and three experimental. The control group received 0.2ml corn oil and the experimental groups were injected with aflatoxin G1 at a dose of $20\mu\text{g}/\text{kg}$ intraperitoneally on days 7, 15 or 35, respectively.

Tissue Preparation & Histopathological Examinations: After the experimental period in each group (day 7, 15 or 35), the kidneys were removed surgically under anesthesia and sterile conditions. The tissue samples were prepared in different ascending alcohol concentrations of 70%, 80%, 90% and 100%. Subsequently, the samples were impregnated with molten paraffin for molding and microscopic examinations. Using a rotating microtome (Germany; serial #: 21074), the paraffin molds were sectioned at a thickness of $5\mu\text{m}$ or $7\mu\text{m}$. The sections were then stained with hematoxylin, eosin and periodic acid Schiff. Finally, the stained sections were examined under light microscopy.

Blood Sampling & Biochemical Tests: After anesthesia with diethyl ether, a blood sample was taken from the hepatic portal vein of each mice under sterile conditions. Subsequently, on days 7, 15 or 35 after treatment with aflatoxin G1, the biochemical analyses were performed to determine

the concentration of serum creatinine, urea, sodium and potassium on a spectrophotometric analyzer (BT-1500; Medsystem, USA).

Real-time Polymerase Chain Reaction: The effect of aflatoxin G1 on aquaporin-1 mRNA expression was analyzed by real-time polymerase chain reaction (PCR). The total RNA was prepared by an isolation kit (Dena Zist; Tehran, Iran) and the quantity and quality of the extracted RNA were tested by nano-drop and gel electrophoresis. Subsequently, a cDNA synthesis kit (Vivantis Technologies, Selangor DE, Malaysia) and SYBR Premix Ex Taq technology (Takara Bio Inc., Japan) were used for additional analyses. Glyceraldehyde-3-phosphate dehydrogenase (GAPDH) as a housekeeping gene, was chosen as the internal control and the changes in relative expression of the target mRNA were determined based on comparative Ct method ($2^{-\Delta\Delta Ct}$). The thermal cycler conditions were 15 minutes at 50°C for the cDNA synthesis, 10 minutes at 95°C followed by 40 cycles of 15 seconds at 95°C to denature the DNA, and 45 seconds at 60°C to anneal and extend the template. The primer sequences were identified as presented in Table 1.

Table 1: Study-designed Primers

Primer	Sense 5'-3'	Anti-Sense 5'-3'
Aquaporin-1	CATCCAGCGGTTAAGTCGAG	CAGTGGGTAATTGAAGCCTAGG
GAPDH (127 bp)	AGAACATCATCCCTGCATCCAC	GTCAGATCCACGACGGACACA

GAPDH: Glyceraldehyde-3-phosphate dehydrogenase

RESULTS

Histological Examinations: In the control group, the microscopic structures of the kidney cells were normal and no specific alterations were observed (Figure 1A). Upon examining the experimental samples for day 7, slight degrees of cellular swelling were observed in the complex distal and proximal tubes (Figure 1B). The microscopic findings for day 15 showed mild degenerations and necrosis in the urinary tract plus mild cell swellings in some of the epithelial cells of the relevant tubes. At some points, focal dilations of the intraglomerular capillaries and increased intraglomerular cells were observed (Figure 1C). On day 35, accumulation of eosinophilic material, i.e., hyaline molds were observed in most ureters along with dilated urethras. In these tubes, the epithelial cells were often elongated with dense, quasi-squamous

nuclei. The atrophy of most glomeruli, dilatation of the urinary tract, necrosis of epithelial cells and complete destruction of some tubes were evident (Figures 1D & 2).

Serum Parameters: The serum concentrations of urea and creatinine in the treatment groups showed a significant increase compared to the control group ($P<0.05$) (Tables 1 & 2). Conversely, the changes in the sodium and potassium concentrations showed significant decreases in the treatment group compared to those in the controls ($P<0.05$) (Tables 3 & 4).

Gene Expression: The expression of aquaporin-1 in mice that received aflatoxin G1 was significantly reduced dose dependently compared to those in the control group ($P<0.05$). Thus, the lowest expression of aquaporin-1 was observed in mice that received aflatoxin G1 for 35 days (Figure 2).

DISCUSSION

Kidneys are very sensitive to toxins because they continually receive a large flow of blood (27). Studies have reported that a major toxic effect of aflatoxin is the induction of adverse effects in renal function (28, 29). Of note, aflatoxin G1 has been known as one of the most abundant sources of contamination in cereals and foods in China (30). In another study conducted in Turkey in 2006, in which the presence of aflatoxin G1 in sesame seeds were investigate, the toxin was surprisingly found in every test sample (31).

The histopathologic data demonstrated that the administration of aflatoxin G1 to mice adversely affected the kidneys, both in the ureters and the glomeruli. The observed histologic lesions included necrosis of the epithelium, hyaline casts, glomerular atrophy, enlargement of intraglomerular capillaries and cells, dilatation of urinary tract, destruction of some ducts, and mild cellular degeneration and swelling within the tubules.

One of the notable observations in the present study was the epithelial cells necrosis. The reviewed literature has reported the aflatoxins B1, B2, G1 and G2 toxicity in rats and mice (28) plus severe necrosis of the epithelial tissue (13, 16). In a population of birds, toxic manifestations of aflatoxin B1 have been reported in the form of tissue necrosis in the tubules of the renal cortex (32).

Induction of kidney damage by aflatoxin B1 has been documented in fish, as the degeneration and necrotic changes of the renal tubes (33).

One of major observations of this study, especially on the 35th day of treatment, was the presence of hyaline casts in the mice ureters. Earlier studies in experimental animals have found the presence of hyaline casts in the kidney tissue upon exposure to aflatoxins (13, 20). The toxicity caused by aflatoxins B1, B2, G1 and G2 in male and female rats has caused the formation of hyaline cast in the distal and proximal convoluted tubes (17, 28).

In the current study, on day 15 of the treatment, histopathological lesions, capillary dilation and focal cell proliferations were noted in the glomeruli. Consistently, tissue atrophy was present around most glomeruli on day 35 of the treatment. Tissue hemorrhage and glomerular atrophy have also been reported after treating a population of pregnant pigs with aflatoxin B1 (34).

Other microscopic observations noted following treatment with aflatoxin G1 consisted of cell swelling in the complex tubes, ductal degeneration, tubular and urethral dilation, and major damages to some ducts. These alterations were largely similar to those reported by a number of earlier studies (13, 20, 28, 35, 36). In the current study, the administration of aflatoxin G1 to the mice in the experimental groups for 7, 15 or 35 days significantly reduced the expression of aquaporin-1 compared to those in the control group ($P < 0.05$). Previous observations have also shown that toxic agents reduce the expression of aquaporin-1 in kidney tissue samples followed by causing significant damages to the kidneys (37, 38).

Our evaluation showed that in the treated mice, serum urea and creatinine levels increased significantly compared to those in the control group ($P < 0.05$), indicative of impaired renal function and protein metabolism (39, 40). In the current study, the serum urea and creatinine concentrations significantly increased in the treated rats after administration of a combination of aflatoxins B1, B2, G1 and G2, consistent with those reported by previous studies (28, 12).

In our study, the serum sodium, potassium and other biochemical parameters related to renal function showed a decreasing trend in the treated groups compared to those in the control group. In the study of Matheus *et al.*, the serum sodium and potassium levels also decreased in piglets fed with a diet contaminated with a combination of aflatoxin and fumonisin, compared with their controls. These findings suggest that the toxins clearly inhibit the activity of sodium-potassium

pump which operates with ATPase (41). Therefore, it can be concluded that kidney damages due to aflatoxin G1 lead to electrolyte imbalance and impaired excretion of the waste products, such as urea and creatinine.

CONCLUSIONS

The findings of this study confirmed that aflatoxin G1 had adverse effects on the mice's renal tissue by reducing the expression of aquaporin-1 by altering the plasma concentration of urea, creatinine, sodium and potassium. Another study has also made similar observations, i.e., aflatoxins B1 and G1 may induce liver and kidney tumors in mice, which highlights the urgency for further studies on this subject (42). We recommend future investigations be conducted on the effects of aflatoxin G1 on other organ tissues.

Ethical Considerations: All institutionally approved ethical principles and guidelines were observed throughout this study.

Funding: This study was funded by the Vice Chancellor for research, Kermanshah University of Medical Sciences, Kermanshah, Iran.

Author's Contributions: *Writing the original draft and planning:* Toraj Zamir-Nasta, Moein Yazdkhasti, Mona Pazhouhi; *Pathological study:* Arash Ahmadi, Toraj Zamir-Nasta, and Kosar Rezaei. *Data analyses:* Cyrus Jalili. *Writing and approval of the manuscript:* All authors.

Conflict of interest: The authors declared no conflict of interest with any internal or external entities.

Acknowledgements: The authors extend their appreciation to Kermanshah University of Medical Sciences for their cooperation and support during the conduction of this study.

REFERENCES

- 1 Luo J, Vogel RF, Niessen L. Rapid detection of aflatoxin producing fungi in food by real-time quantitative loop-mediated isothermal amplification. *Food Microbiology*. 2014;44:142-148.

- 2 Moeinian K, Yaghmaeian K, Ghorbani R. Aflatoxin M1 concentration in raw milk produced in the cities of Semnan province-Iran. *Koomesh*. 2014;176-181.
- 3 Jalili C, Zamir-Nasta T, Ghahari L, Kakeh baraei S. Relationship between synthesis of P21 and Cyclin D1 proteins and histomorphometric parameters of mice testicular tissue in presence of Aflatoxin G1. *Koomesh*. 2019;21(1):195-200.
- 4 Al-Zoreky NS, Saleh FA. Limited survey on aflatoxin contamination in rice. *Saudi Journal of Biological Sciences*. 2019; 26(2): 225-231.
- 5 Ali S. The study of aflatoxin types and methods of detection, purification, identification and their effects on human and animal. *Sci Road J*. 2015;3:229-235.
- 6 Minto RE, Townsend CA. Enzymology and molecular biology of aflatoxin biosynthesis. *Chemical Reviews*. 1997;97(7):2537-2556.
- 7 Wogan GN. Aflatoxin as a human carcinogen. *Hepatology*. 1999;30(2):573-575.
- 8 Wangikar P, Dwivedi P, Sinha N, Sharma A, Telang A. Teratogenic effects in rabbits of simultaneous exposure to ochratoxin A and aflatoxin B1 with special reference to microscopic effects. *Toxicology*. 2005;215(1-2):37-47.
- 9 Salunkhe D, Desai B, Bhat N. *Vegetable and flower seed production*: Agricole Publishing Academy; 1987.
- 10 Marquardt RR, Frohlich AA. A review of recent advances in understanding ochratoxicosis. *Journal of Animal Science*. 1992;70(12):3968-3988.
- 11 Prabu P, Dwivedi P, Sharma A. Toxicopathological studies on the effects of aflatoxin B1, ochratoxin A and their interaction in New Zealand White rabbits. *Experimental and Toxicologic Pathology*. 2013;65(3):277-286.
- 12 Kanchana K, Hedhayathullahkhan HB, Vedagiri A, Palanivelu S, Panchanatham S. Pharmacological effect of Kalpaamrutha on renal and cardiac damage induced by ingestion of aflatoxin B1 studied in wistar rats. *Biomedicine & Preventive Nutrition*. 2013;3(3):233-240.
- 13 Fetaih HA, Dessouki AA, Hassanin AA, Tahan AS. Toxopathological and cytogenetic effects of aflatoxin B1 (AFB1) on pregnant rats. *Pathology Research and Practice*. 2014;210(12):1079-1089.
- 14 Sharma V, Sharma C, Paliwal R, Pracheta SS, Sharma S. Ameliorative effects of Curcuma longa and curcumin on aflatoxin B1 induced serological and biochemical changes in kidney of male mice. *Asian J Biochem Pharmaceut Res*. 2011;2(1):338-351.
- 15 Abdulmajeed NA. Therapeutic ability of some plant extracts on aflatoxin B1 induced renal and cardiac damage. *Arabian Journal of Chemistry*. 2011;4(1):1-10.
- 16 Sharma V, Gupta R, Sharma S. Antiaflatoxicogenic activities of tinospora cordifolia root extract against aflatoxin b1-induced renal damage. *International Journal of Pharmacy and Pharmaceutical Sciences*. 3(4):326-329

- 17 Abdel-Wahhab MA, Omara EA, Abdel-Galil MM, Hassan NS, Nada SA, Saeed A, et al. Zizyphus spina-christi extract protects against aflatoxin B1-initiated hepatic carcinogenicity. *African Journal of Traditional, Complementary, and Alternative Medicines*. 2007;4(3):248-256.
- 18 Akao M, Kuroda K, Wogan G. Aflatoxin B1: The kidney as a site of action in the mouse. *Life Sciences*. 1971;10(9):495-501.
- 19 Croy RG, Wogan GN. Quantitative Comparison of Formed in Rat and Mouse Covalent Aflatoxin-DNA Livers and Kidneys. *Journal of the National Cancer Institute*. 1981;66(4):761-768.
- 20 Fahmy A. Histological and Immunohistochemical study on the possible protective effects of curcumin and garlic against aflatoxinB1 induced toxicity on the renal cortex of adult male guinea pig. *J Am Sci*. 2017;13(3):115-124.
- 21 Abreu-Rodríguez I, Silva RS, Martins AP, Soveral G, Toledo-Aral JJ, López-Barneo J, et al. Functional and transcriptional induction of aquaporin-1 gene by hypoxia; analysis of promoter and role of Hif-1 α . *PLoS One*. 2011;6 (12). Doi.org/10.1371/journal.pone.0028385.
- 22 Xu W-H, Shi S-N, Xu Y, Wang J, Wang H-K, Cao D-L, et al. Prognostic implications of Aquaporin 9 expression in clear cell renal cell carcinoma. *J Transl Med*. 2019;17(1):363 . Doi.org/10.1186/s12967-019-2113-y.
- 23 Sfera A, Osorio C. Water for thought: is there a role for aquaporin channels in delirium? *Frontiers in Psychiatry*. 2014;5:57. Doi.org/10.3389/fpsyt.2014.00057.
- 24 Khan MR, Allothman ZA, Ghfar AA, Wabaidur SM. Analysis of aflatoxins in nonalcoholic beer using liquid-liquid extraction and ultraperformance LC-MS/MS. *Journal of Separation Science*. 2013; 36(3):572-577.
- 25 Shen H, Lv P, Xing X, Xing L, Yan X, Wang J, et al. Impairment of alveolar type-II cells involved in the toxicity of Aflatoxin G1 in rat lung. *Food and Chemical Toxicology*. 2012;50(9):3222-3228.
- 26 Mousavi SSB, Soleimani A, Mousavi MB .Epidemiology of end-stage renal disease in Iran: a review article. *Saudi Journal of Kidney Diseases and Transplantation*. 2014;25(3):697-702.
- 27 Ammann HM. Is indoor mold contamination a threat to health? Part two. *Journal of Environmental Health*. 2003; 66(2):47-49.
- 28 Abdel-Fattah SM, Sanad M, Safaa M, Ragaa F. The protective effect of white ginseng against biochemical and pathological changes induced by aflatoxins in rats. *J Am Sci*. 2010;6(12):461-472.
- 29 Emam EEaH, S.H. M. Improvement of the fertility and some biochemical effects of aflatoxin on male rabbit by ginseng. *Assiut Vet Mid Journal*. 2008;54 (116):302-314.
- 30 Zhang X, Wang F, Wang J, Yan X, Huang X, Xie T, et al. Experimental lung carcinoma induced by fungi and mycotoxins--a review. Beijing da xue xue bao Yi xue ban= *Journal of Peking University Health Sciences*. 2003;35(1):4-6.

- 31 Yentür G, Er B, Özkan MG, Öktem AB. Determination of aflatoxins in peanut butter and sesame samples using high-performance liquid chromatography method. *European Food Research and Technology*. 2006;224(2):167-170.
- 32 Yasir IH. Toxicological pathology of aflatoxin b1 in local pigeon mainly in liver, kidney and heart. *Journal of International Academic Research for Multidisciplinary*. 2016;4:218-227.
- 33 Sahoo P, Mukherjee S, Nayak S, Dey S. Acute and subchronic toxicity of aflatoxin B 1 to rohu rohita (Hamilton). *Indian Journal of Experimental Biology*. 2001;39(05):453-458.
- 34 Shivasharanappa GY, Mundas S, Rao D, Tikare V, Shridhar N. Histopathological changes in pigs exposed to aflatoxin B1 during pregnancy. *Indian Journal of Animal Research*. 2013;47(5):386-391.
- 35 Abdul-Ameer HH, Jaffar AA, Al-Habib MFM. Aflatoxin B1-induced kidney damage in rats. *Journal of the Faculty of Medicine, Baghdad*. 2007;49(1):147-150.
- 36 Kamel ES. Histological study on the effect of aflatoxin B1 on the renal tubules of adult rats. *Egyptian Journal of Histology*. 2013;36:246-252.
- 37 Parvardeh S, Mohseni Kouchsfahani H, Nebyunii M. The Effect of Green Tea Hydroalcoholic Extract of Camellia Sinensis on AQP1 Gene Expression in Proximal Tubuls of Gentamicin Treated Rat kidney. *Armaghane Danesh*. 2018;23(2):146-159.
- 38 Abreu-Rodríguez I, Silva RS, Martins AP, Soveral G, Toledo-Aral JJ, López-Barneo J, *et al*. Functional and transcriptional induction of aquaporin-1 gene by hypoxia; analysis of promoter and role of Hif-1 α . *PloS one*. 2011;6(12):e28385.
- 39 Anwar K. Cypermethrin, a pyrethroid insecticide induces teratological and biochemical changes in young chick embryos. *Pakistan J Biol Sci*. 2003;6(19):1698-1705.
- 40 Abdel-Wahhab MA, Aly SE. Antioxidants and radical scavenging properties of vegetable extracts in rats fed aflatoxin-contaminated diet. *Journal of Agricultural and Food Chemistry*. 2003;51(8):2409-2414.
- 41 Baldissera MD, Müller LK, Souza CF, Santurio JM, Gloria EM, Machado G, *et al*. Creatine kinase and ATPase activities in piglets fed a fungal mycotoxin co-contaminated diet: Consequences in the pathogenesis of subclinical intoxication. *Microbial Pathogenesis*. 2018;122:13-18.
- 42 Butler W, Greenblatt M, Linksy W. Carcinogenesis in rats by aflatoxins B1, G1, and B2. *Cancer Research*. 1969;29(12):2206-2211.

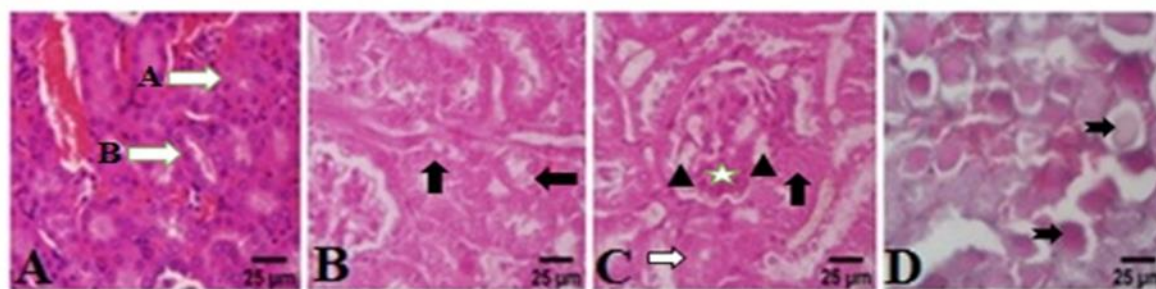
FIGURES

Figure 1: Microscopic view of (A) a normal kidney (control group) (the natural structure of the proximal convoluted tubule (arrow A) and the distal convoluted (arrow B), (B) mild cell swelling (treatment group, day 7) (the presence of amorphous and transparent spaces in the cytoplasm of urethral epithelial cells (black arrows), and (C) degeneration and necrosis (treatment group, day 15) (White arrow indicates the presence of amorphous clear space (cell swelling) and black arrow indicates karyolysis of the nucleus (necrosis) in the epithelial cells of the urethra. Note the dilation of the capillaries inside the glomerulus (D) (treatment group, day 35). Note the deposition of eosinophilic material (hyaline cast) widely (black arrow) and dilation of the urinary tract. H&E stain, mag. x40.

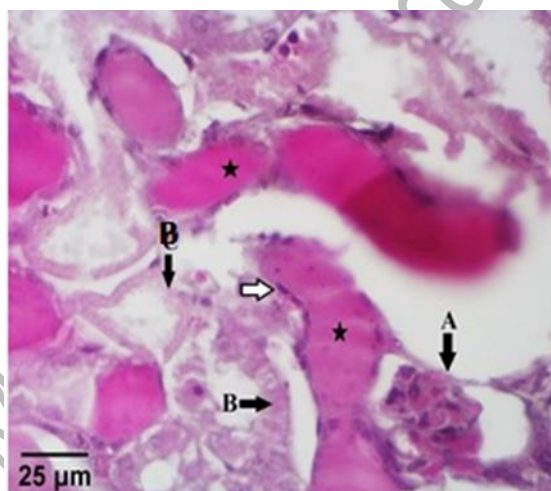


Figure 2: Microscopic view of the kidney tissue. Treatment group day 35. Pay attention to the accumulation of eosinophilic material (hyaline cast) inside the urinary tract (star) and necrosis of urethral epithelial cells (arrow B). Arrow A shows glomerular atrophy, arrow B shows necrosis (karyolysis) of the urethral epithelial cell, and white arrow shows deformity of the epithelial cells. PAS, mag. x40.

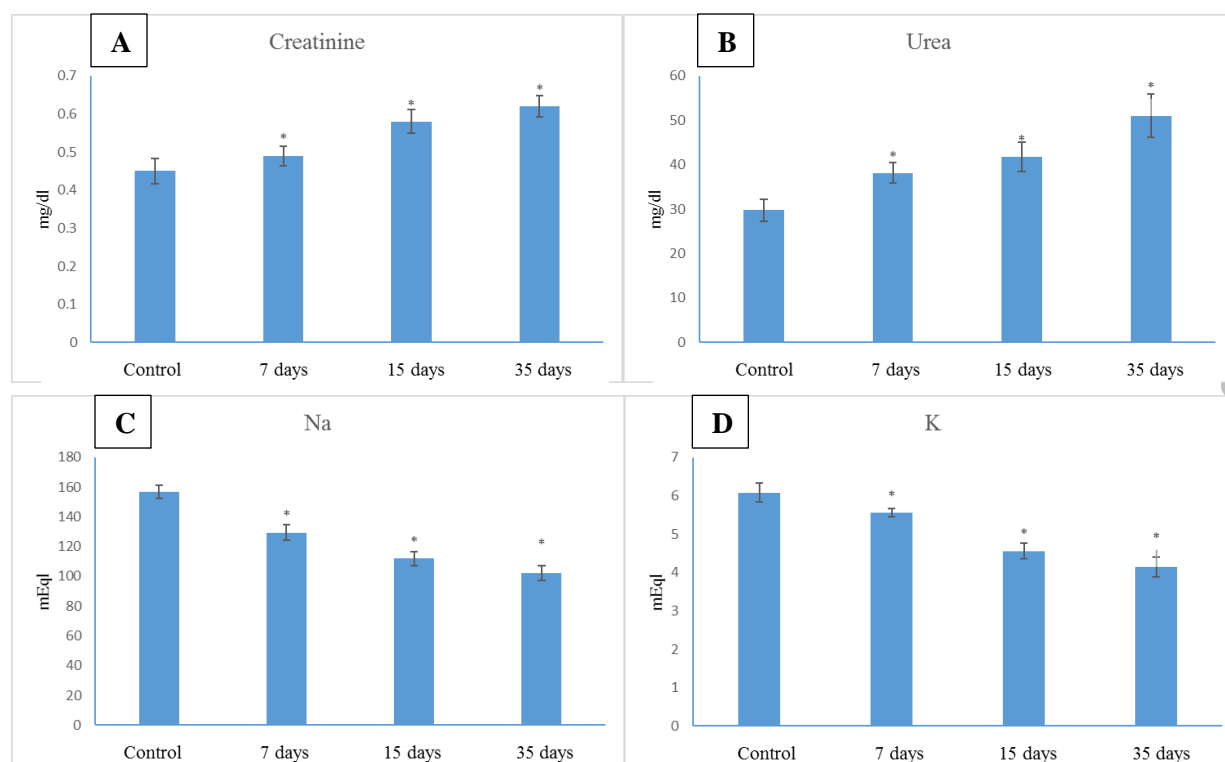


Figure 3: Effect of aflatoxin G1 on plasma levels of (A) creatinine, (B) urea, (C) Na⁺ and (D) K⁺ in mice. *Values are statistically significant ($P < 0.05$). Data are presented as mean \pm standard deviation.

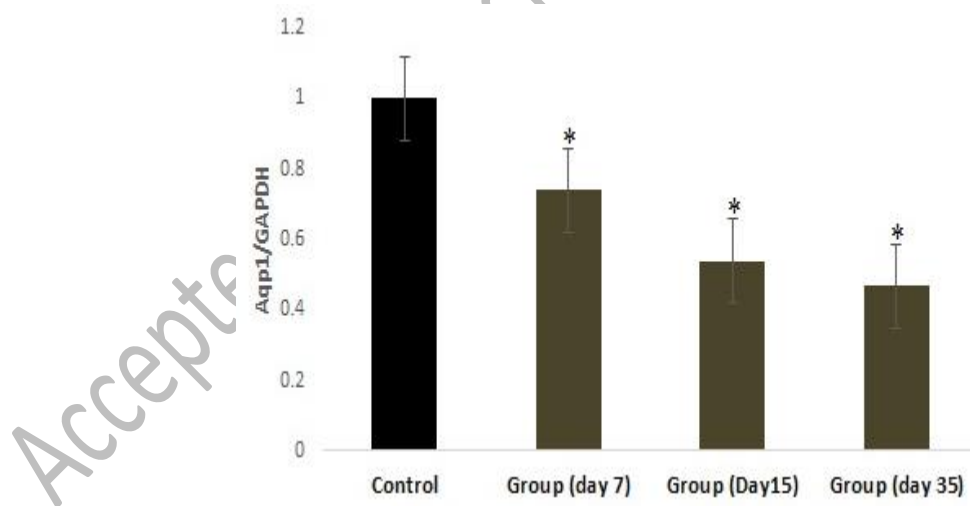


Figure 4: Effect of aflatoxin G1 on the expression level of aquaporin-1 mRNA was measured by real time-PCR. All data have been expressed based on mean \pm SD. * = Indicates significant difference. ($P < 0.05$).